



## **Standard of Care: Reverse/Inverse Total Shoulder Arthroplasty**

### **Case Type / Diagnosis:**

The reverse or inverse total shoulder arthroplasty (rTSA), first described by Grammont et al.<sup>11</sup> has only recently gained popularity and FDA approval as a treatment option for patients requiring a shoulder replacement for the treatment of glenohumeral (GH) arthritis when it is associated with irreparable rotator cuff damage, complex fractures, as well as for a revision for a previously failed conventional TSA in which the rotator cuff tendons are deficient/absent. The rTSA prosthesis has been used in Europe for nearly twenty years with good outcomes in regards to pain and function for the treatment of the rotator cuff deficient/absent shoulder.<sup>6, 11, 19</sup> Prior to rTSA, surgical options for the above impairments usually included a Total Shoulder Arthroplasty (TSA) or Humeral Head Arthroplasty (HHA). Outcomes for patients with rotator cuff deficiency having undergone a Total Shoulder Arthroplasty (TSA) or Humeral Head Arthroplasty (HHA) have not been uniform.<sup>2, 8, 13, 22, 23, 26, 27</sup> Given that the glenohumeral mechanics are altered in the rotator cuff deficient shoulder, conventional TSA prosthesis have yielded limited results. As the muscle tone and tissue of the rotator cuff deteriorate, the center of rotation of the GH head changes resulting in eccentric loading of the glenoid component of a traditional TSA prosthesis. This “rocking horse” effect, as described by Matsen, has been implicated in early arthroplasty failure, particularly of the glenoid component,<sup>10, 12</sup> As a result of these poor results, HHA (do you mean HHA)? had been the preferred operative method in the presence of a deficient/absent rotator cuff. This surgical option, similar to the conventional TSA, has been shown to yield limited outcomes in regards to functional improvement and fair improvements in pain.<sup>1, 8, 17, 22</sup> The rTSA has recently become a favorable surgical intervention with rotator deficient/absent shoulders.

The rTSA changes the orientation of the shoulder joint by replacing the glenoid fossa with an artificial glenoid base plate and glenosphere; and the humeral head with a shaft and concave cup that both lateralizes and distalizes the humeral shaft (refer to Figure 1).



Figure 1. Reverse Total Shoulder Arthroplasty Components. The prosthesis has 5 parts: the glenoid base, the glenosphere, a polyethylene cup, humeral neck, and the humeral stem.

With the rTSA, the center of rotation of the shoulder joint is moved medially thus decreasing joint reactive forces across the glenoid base plate. The humeral cup displaces the humerus distally, which subsequently increases the deltoid lever arm and overall deltoid tension. This altered anatomy leads to an enhanced function of the deltoid, which compensates for the

deficient/absent rotator cuff. In essence, the rTSA provides a fulcrum and increases deltoid tension, which reverses the changes associated with rotator cuff deficiency/arthropathy and its resultant superior migration. (Figure 2 depicts native shoulder joint with deltoid lever arm. Figure 3 depicts rTSA with altered deltoid lever arm).

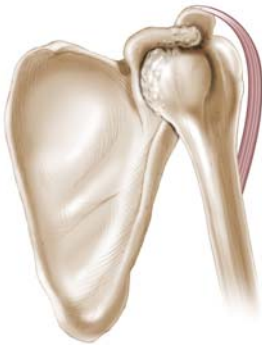

Figure 2

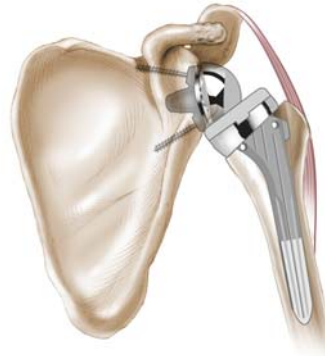


Figure 3

Active humeral head depression from the rotator cuff is not required with rTSA as this is created by the prosthetic design. The deltoid compensates for rotator cuff deficiency and becomes the primary elevator of the shoulder joint. By recreating an appropriate center of rotation and fulcrum with improved deltoid mechanics, functional range of motion may be restored.

The rotator cuff is either absent or minimally involved with the rTSA; therefore, the postoperative management for a patient following the rTSA is different than the rehabilitation following a traditional TSA or HHA. Additionally, as the biomechanics of this prosthesis are markedly different, and because there is an inherent potential for instability due to its design, precautions for the rTSA are unique and markedly different than those developed for TSA or HHA. The surgeon, physical therapist and patient need to take this into consideration when establishing the postoperative treatment plan.

**Possible ICD. 9:**

Proximal Humeral Fracture-Open	812.10
Shoulder Pain	719.41
Osteoarthritis of Shoulder	715.91
Rotator Cuff Syndrome	726.10
Shoulder Dysfunction	726.20

**Indications for Treatment:**

Status post rTSA secondary to glenohumeral (GH) arthritis with irreparable rotator cuff damage, complex fractures or revision of a failed TSA/HHA with deficient / absent rotator cuff tendons.

## **Contraindications / Precautions for Treatment:**

### Shoulder Dislocation Precautions:

- **No shoulder motion behind back. (NO combined shoulder adduction, internal rotation, and extension.)**
- **No glenohumeral extension beyond neutral.**
- **Functionally, no shoulder movement behind the back.**
- **Avoid pure shoulder abduction.**

Above precautions should be implemented for 12 weeks postoperatively unless surgeon specifically advises patient or therapist differently.

## **Evaluation:**

**Medical History:** Review medical history questionnaire (on an outpatient/ambulatory evaluation), patient's medical record (during the inpatient/acute stay) and medical history reported in the BWH Longitudinal Medical Record (LMR). Review any diagnostic imaging, tests, work up and operative report listed under LMR.

**History of Present Illness:** Interview patient at the time of examination to review patient's history and any relevant information that would pertain to current status. If the patient is unable to give a full history, then interview the patient's legal guardian or custodian. Determine any applicable past injuries that have taken place. Some examples of previous injury could be history of trauma, history of OA, history of shoulder joint related problems. Review the attending surgeon's notes to determine underlying pathology/cause leading to the rTSA.

**Social History:** Review patient's home, work, recreational and social situation. Areas to focus on would be any upper extremity weight-bearing activity, excessive reaching, lifting or carrying loads with upper extremities.

**Medications:** The surgeon initially prescribes postoperative pain medication and then patients are weaned to anti-inflammatory medication as needed.

## **Examination**

This section is intended to capture the most commonly used assessment tools for this case type/diagnosis. It is not intended to be either inclusive or exclusive of assessment tools.

**Pain:** As measured on the visual analogue scale (VAS), activities that increase symptoms, decrease symptoms, identify location of symptoms.

**Visual Inspection:** Assess integument integrity; the quality of the incision, ensuring there are no signs of irritation/infection.

**Palpation:** Palpate shoulder complex. Focus is on presence and extent of musculature atrophy, swelling and general soft tissue consistency.

**ROM:** Initial ROM assessment is contingent upon post-operative day tissue quality ROM restrictions. Refer to attached protocol for appropriate progression or specific surgeon orders for ROM delay if necessary.

**Strength:** Early post-op motor control should be assessed for the distal upper extremity musculature by evaluating active range of motion and gentle resisted isometric as needed for assessment only. Manual muscle testing will be deferred until post-operative healing has occurred. Refer to specific time frames on protocol.

**Sensation:** General upper extremity dermatomal screen. If abnormal as found via dermatomal screen or if diabetic, further assessment would be indicated.

**Posture/alignment:** Primary focus on supine, sitting and standing positioning. Focus on avoiding shoulder extension and combination of shoulder internal rotation, adduction and extension at all times during the 0-12 week postoperative period.

**Gait & Balance:** Gross assessment to determine patient's safety to ensure independence with transfers, gait on level surfaces and with stair negotiation. Further assessment warranted if impairments noted during screening.

**Differential Diagnosis:** Consider if patient has any co-morbid issues and/or postoperative complications that directly affect postoperative progression. (i.e. musculocutaneous nerve palsy, etc..)

**Functional Assessment:**

Use of a shoulder specific functional capacity questionnaire is recommended to establish postoperative status and to objectively and subjectively monitor progress. Typically, it is recommended to begin the use of functional outcome measures by the end of the first month postoperatively and then monthly until discharge from skilled therapy services.

Potential tools:

- Simple Shoulder Test (SST)
- American Shoulder and Elbow Surgeon's Shoulder Evaluation Short Form (ASES-SF)
- Shoulder Pain and Disability Index (SPADI)

The SST<sup>14</sup> and the ASES-SF<sup>21</sup>, which are both standardized self-assessments of shoulder function have been found to have fairly high responsiveness as well as high test-retest reliability as compared to other shoulder outcome tools.<sup>4</sup> The SST has a standardized response mean of 0.87, confidence interval 0.52, 1.22; while the ASES-SF had a standardized response mean of 0.93, confidence interval 0.57, 1.29. The intra-class correlation coefficients for the SST and ASES-SF are 0.99 and 0.96, respectively. They both are very simple and quick for the subject and investigator to fill out. The SST has been shown to be sensitive for various shoulder conditions as well as sensitive to detect changes in shoulder function over time.<sup>15,16</sup> The SPADI is another subjective questionnaire that has a pain and disability/function components. This scale uses a visual analog scale to measure pain while subjective questions are used to assess function of the shoulder. The pain and function components are weighted accordingly since there are 5 pain scales and 8 functional questions, and then the total score is computed by averaging the pain and functional score. With the SPADI, unlike the other outcome measures a higher value indicates greater pain and disability.

**Assessment:**

Establish diagnosis and need for skilled intervention

**Potential Problem List:**

1. Pain
2. Impaired Shoulder ROM
3. Impaired Strength
4. Impaired Shoulder mechanics
5. Impaired Function when compared to baseline
6. Impaired Knowledge of Activity Modification / Postoperative precautions
7. Impaired Knowledge of Rehabilitation Progression

**Prognosis:**

Regardless of underlying pathology, operative technique is crucial for a good outcome following rTSA. It is critical to realize that the complication rate of this procedure varies depending upon the indication for prosthesis insertion. Primary placement for uncomplicated rotator cuff deficiency in the presence of good bone stock is the optimal environment and situation to implant the rTSA. Complication rates for this application may be as low as two to three percent. The placement of rTSA in a revision setting with poor or absent bone stock, which entails removing a previous humeral component, may have a complication rate that exceeds twenty percent. Common complications include, but are not limited to component instability or dislocation, nerve damage, intra-operative fracture, infection, hematoma, and hardware failure. Additionally, patient improvement

is variable and may be affected by the status of the posterior rotator cuff, component placement, previous operations and quality of surrounding bone and soft tissues.

Collaboration between the surgeon and physical therapist is essential to ensure appropriate rehabilitation for a patient following rTSA. Therapists need to be aware of a number of factors that may affect successful or optimal rehabilitation. They include the patient's preoperative shoulder status, type of implant used, the glenoid and humeral bone quality, the integrity of the remaining rotator cuff, concomitant rotator cuff repair or tendon transfer, and the overall component stability at the time of surgical reconstruction.

The surgical approach needs to be considered when devising the postoperative plan of care. Traditionally a rTSA procedure is surgically performed via a typical deltopectoral approach, which minimizes surgical trauma to the anterior deltoid. However, some surgeons perform this procedure via a superior approach, retracting the anterior deltoid from the anterior lateral one third of the clavicle, a sub deltoid approach.<sup>3</sup> This allows for superior exposure to the glenohumeral joint between the retracted anterior deltoid and the clavicle. Upon surgical closure the anterior deltoid is sutured back to its anatomical location. In these cases early deltoid activity is contraindicated. It is recommended that a variation of the attached protocol be implemented. Postoperatively the patient should use a sling for 4-6 weeks, delay deltoid isometrics for at least four weeks, do not begin active range of motion (AROM) flexion for at least six weeks, and no deltoid isotonic strengthening for at least 12 weeks.

Patient's postoperative activity level expectations also needed to be considered when establishing the postoperative rehabilitation plan. There is a wide variance in functional and ROM outcomes following rTSA and patients need to be reminded that their shoulder mechanics and function will have some limitations when compared to their unaffected shoulder. Patients with more active lifestyles typically will require additional education regarding their restrictions to ensure proper longevity of their new prosthesis as well as to minimize their risk for dislocation.

**Goals:** (with measurable parameters and with specific timelines)

1. Minimize Pain
2. Enhance functional AROM (typically greater than 90 degrees of elevation)
3. Enhance Strength/muscle performance
4. Enhance Function

**Age Specific Considerations:**

Although there are no age specific guidelines, a rTSA is typically indicated for the older patient, 65-70 years of age. Given that inclusion criteria is based generally on a severely arthritic glenohumeral joint with significant rotator cuff arthropathy, the younger population generally will not present with this late stage disease progression.

## Treatment Planning / Interventions

Established Pathway  Yes, see attached.  No

Established Protocol  Yes, see attached.  No

### **Interventions most commonly used for this case type/diagnosis:**

This section is intended to capture the most commonly used interventions for this case type/diagnosis. It is not intended to be either inclusive or exclusive of appropriate interventions.

There are three primary postoperative rehabilitation concepts that need to be considered when outlining the care for a patient following rTSA:

- joint protection
- deltoid function
- establishment of appropriate functional and ROM expectations.

Regarding joint protection, postoperative positioning and activity need to be appropriately established since there is a higher risk of shoulder dislocation following rTSA than a conventional TSA. Patients with rTSA typically do not dislocate with the surgical arm in abduction and external rotation as generally seen with native shoulders or those who have undergone conventional TSA or HHA. If rTSA prostheses dislocate, they do so typically with the surgical arm in internal rotation and adduction in conjunction with extension. This position allows the prosthesis to escape anteriorly and inferiorly which is the position of greatest vulnerability for the rTSA. Thus, tucking in a shirt with the operative upper extremity and reaching behind one's back are predominantly dangerous activities particularly in the immediate post operative phase and should be the main postoperative precautions for no less than the first 12 weeks.

Enhancement of deltoid function in the absence of the rotator cuff following an rTSA is the most important rehabilitation concept that the postoperative strengthening protocol is based on. As previously stated, stability and mobility of the shoulder joint is now largely dependent upon the deltoid and periscapular musculature.

Any return of active rotation will be dependent upon the postoperative condition of the teres minor, infraspinatus and deltoid. Hence, the expectation for functional and ROM gains should be set on a case-by-case basis depending upon underlying pathology, the presence or absence of the above musculature and the degree to which one's deltoid and periscapular musculature can be rehabilitated. The treating clinician must remember that normal / full active ROM of the shoulder joint following rTSA is not expected; however, functional active elevation of at least 105 degrees should be anticipated.

It cannot be overstressed how critical the status of the posterior cuff is. Meticulous pre-operative evaluation to assess the capacity to actively external rotate the humerus has a profound effect on the overall function after rTSA. In particular, a positive hornblower's sign should compel the surgeon to strongly consider a concomitant latissimus dorsi tendon transfer. Active forward flexion without external rotation may create a markedly dysfunctional upper extremity and lead to poor patient satisfaction, regardless of the intensity and effort of the patient and physical therapist post-operatively.

A postoperative rTSA physical therapy treatment protocol is outlined in 4 phases: phase I – immediate post surgical, phase II – active range of motion / early strengthening, phase III – moderate strengthening, and phase IV – independent/progressive home program. Each phase is structured based on postoperative timelines that respect healing and soft tissue parameters; however, the use of an evaluation based method<sup>18</sup> in conjunction with healing timeframes to progress a patient through the protocol based on their intraoperative/postoperative findings, clinical presentation and achievement of clinical goals/milestones is important.

Phase I, the immediate Post Surgical Phase lasts or occurs from postoperative day 1 to the end of the 6<sup>th</sup> postoperative week. The goals during this phase are to restore independent bed mobility, transfers and ambulation, and to maintain the integrity of the replaced joint while restoring passive ROM. Family / care giver involvement during this time is critical to ensure proper positioning, posture and joint protection. Shoulder extension and the combination of internal rotation and adduction be avoided during static positioning, exercise and activities of daily living (ADLs). See rTSA protocol for details associated with any phase.

Patients that have required rTSA for a revision of a failed conventional TSA, the repair of a nonunion fracture, or any other pathology in which the shoulder stability is significantly compromised as assessed by intraoperative inspection, need to be managed on a case-by-case basis. In general these patients will require a period of time in which scar tissue must adequately develop to provide shoulder stability in the absence of a competent rotator cuff and compromised capsule. In these cases, the delay of all shoulder ROM for 3-6 weeks postoperatively is recommended. Close collaboration with the referring surgeon regarding the structural integrity of the reconstructed shoulder is essential to determine the ideal time to begin shoulder ROM activity. Patient and caregiver education, understanding and compliance of the needed joint protection techniques remains critical.

When the structural stability of the reconstructed shoulder is adequate, such as with a primary rTSA, protected passive ROM may begin after the effects of the intrascapular block have resolved to ensure proper deltoid function as well as to ensure the patient's sensory feedback mechanisms are intact. Due to the high rate of postoperative dislocation, it is important not to over stress the shoulder joint, as this may result in hypermobility/instability. It is important that the patient is able to provide adequate feedback regarding pain and end feel. Shoulder immobilization in an abduction type



sling, which supports the humerus in the position of the scapular plane (30 degrees of elevation and abduction) for the first 3 to 4 weeks, except during their therapy, bathing and home exercises is typically recommended. This is consistent with Grammont's<sup>11</sup> postoperative recommendations. The critical concept regarding positioning that the patient must adhere to following rTSA is that they "should always be able to see their elbow regardless of what they are doing". This positioning in essence ensures that their upper extremity remains in slight forward flexion and is not placed in extension or in pure abduction. In addition, when the patient is out of their immobilizer they should be advised not to reach across their abdomen/chest wall with their operative upper extremity as this involves combined internal rotation with adduction and again increases their risk of dislocation.

When the posterior cuff has been surgically repaired and/or its tendon quality is poor during intraoperative inspection, routinely an external rotation immobilizer like the Donjoy Ultrasling 15 degree ER sling (dj Orthopedics, Vista, Ca) is used. The positioning that an external rotation immobilizer provides will still allow the humerus to be in the position of the scapular plane (30 degrees of elevation and abduction) with the added benefit of neutral to 15 degrees of external rotation. This promotes the posterior rotator cuff to be held in a relatively shortened position during the crucial early postoperative healing phase. This positioning may provide an enhanced opportunity for the posterior rotator cuff to heal as it promotes immobilization in a relatively shortened position. Empirically, we have seen less external rotation stiffness and better tolerance to external rotation PROM postoperatively. We have not studied whether this alternative positioning has had an impact on postoperative posterior cuff healing and/or muscular performance. Additionally, this position has shown to have an inherently lower dislocation rate with the rTSA.

In addition, when tissue integrity of the posterior rotator cuff is of concern at the time of surgical repair and/or the patient is at a high risk for dislocation, early immobilization in a rigid gunslinger type orthosis may be warranted. Typically, the gunslinger settings are 30 degrees of abduction, maximal forward flexion as allowed by the brace, and neutral to maximal external rotation. However, the exact positioning is set by the surgeon on a case by case basis based on the integrity of the surgical repair.

Frequent and continuous cryotherapy postoperatively is used to assist in the control of pain, minimizing swelling and muscle spasm, and to suppress inflammation. The analgesic effects occur after tissue is cooled to between 50 and 60 degrees F,<sup>20</sup> although the actual depth of cooling is unknown. The efficacy of cryotherapy for postoperative use is typically based on poorly controlled studies and empirical evidence. However, Speer et al<sup>24</sup> reported in a very sound prospective, randomized, controlled clinical trial on 50 subjects following shoulder surgery that cryotherapy when used every 1-2 hours for the first 24 hours postoperatively, and then decreased to 4-6 times per day or as needed until reassessment time on the tenth postoperative day, found that individuals using cryotherapy had less pain over the first 24 postoperative hours with a better potential for

sleep and less of a need for pain medication. The subjects receiving cryotherapy reported diminished shoulder pain and swelling. Shoulder movement was less painful during therapy by 10 days postoperatively; therefore, enabling these patients to better follow through with their rehabilitation.

During phase I all shoulder activity should be passive to minimize loads to the newly reconstructed joint. Active or active assisted elbow, wrist, and hand activity is appropriate provided that the shoulder joint remains statically positioned. During the first 4 postoperative days, typically while the patient is in inpatient/acute care, PROM is limited in order to minimize strain on the shoulder and to allow for the initial stages of tissue healing. Flexion and elevation in the plane of the scapula are gradually increased as tolerated until reaching 90 degrees. Pure shoulder abduction is not recommended as it may place undue stress on the potentially repaired / reattached subscapularis. Rational for this is when performing pure abduction there is a significant amount of stress placed on the subscapularis and anterior structures of the shoulder. Passive external rotation should be progressed to approximately 20-30 degrees while in the scapular plane. However, if the subscapularis was repaired this external rotation ROM parameter may need to be adjusted as to not place undue stress on the repair. Discussion with the referring surgeon is recommended to ensure initial external rotation ROM is performed in a range that does not risk disruption of the surgical repair. Due to the complication of dislocation, no internal rotation ROM for the first 6 postoperative weeks is recommended. Periscapular sub-maximal pain free isometrics and sub-maximal pain free deltoid isometrics with the humerus protected in the scapular plane should begin around the 4<sup>th</sup> postoperative day. Given that there is minimal to no intact rotator cuff following rTSA the deltoid and periscapular musculature are the primary dynamic restraints, stabilizers, and movers of the glenohumeral joint. Beginning sub-maximal pain free isometrics will restore deltoid firing, thus providing stability to the glenohumeral joint. This isometric activity is initiated to begin regaining adequate upper back and shoulder girdle strength as the periscapular musculature along with the deltoid are now integral to shoulder function following rTSA. Avoidance of shoulder hyperextension while performing posterior deltoid isometrics is critical to minimize the risk of dislocation.

During the 3<sup>rd</sup> through the 6<sup>th</sup> postoperative week the initial post surgical phase activities are progressed based on the clinical progression and presentation of the patient. Initial soft tissue healing has occurred and the patient's sensory feedback has improved which allows a safer progression of passive forward flexion and elevation in the scapular plane to 120 degrees. After the 6<sup>th</sup> postoperative week passive ROM of flexion and elevation in the scapular plane may be advanced to patient tolerance, generally 140 degrees. Most reported outcomes of patients following rTSA achieve upwards to 138 degrees of active elevation.<sup>5, 6, 9, 25</sup> Passive external rotation ROM may gradually be progressed to 30-45 degrees (in the scapular plane), while respecting the soft tissue constraints of the subscapularis (if attached or still intact). The initiation of passive internal rotation may begin during the 6<sup>th</sup> postoperative week and should only be completed in a protected

position of at least 60 degrees of abduction in the scapular plane to ensure avoidance of internal rotation with adduction.

Phase II, the active range of motion/ early strengthening phase at weeks six to twelve, consists of the progression from PROM to active assisted/active range of motion (AA/AROM), as well as the initiation of gentle strengthening with the primary focus of restoring dynamic shoulder stability and enhanced mechanics. Previously stated dislocation precautions should continue to be strictly enforced. Adequate healing at 6 weeks postoperatively allows for AA/AROM to be safely initiated. The therapist must carefully monitor quality of movement patterns, patient's motor control and overall shoulder stability while progressing from the patient's program from AAROM to AROM. This should ensure that the shoulder musculature is not inappropriately challenged, which may lead to the development of poor mechanics, unnecessary pain, and compromised joint integrity. AAROM and AROM forward flexion and elevation in the plane of the scapula should be initiated supine where the scapula is stabilized. These activities should then be progressed to more functional and dynamically challenging positions of sitting and standing. AA/AROM IR and ER may be initiated and progressed similarly, yet it is still imperative to maintain the rotation movements to within the scapular plane.

The initiation of IR and ER sub-maximal isometrics are typically delayed until the 8<sup>th</sup> week postoperatively in order to respect the soft tissue integrity of the subscapularis and teres minor. Depending upon intraoperative soft tissue inspection of the subscapularis it may or may not be surgically reattached to the new rTSA prosthesis. Typically the infraspinatus is irreparable and the teres minor intact. Beginning IR or ER isometrics at an earlier time in the rehabilitation process may lead to re-tearing if any of the rotator cuff was surgically repaired. If the cuff was not repaired, consultation with the referring surgeon should occur to establish whether IR and ER isometrics might be initiated earlier than 8 weeks postoperatively since the risk of rotator cuff tearing is not a concern.

Gentle periscapular and deltoid isometric activity should progress to isotonic activity between the 6<sup>th</sup> and 8<sup>th</sup> postoperative week. When isolating the posterior deltoid, patients need to be reminded that the shoulder should not extend past neutral as this could lead to excessive stressors placed on the anterior tissues. Initiation of isotonic strengthening should only commence when adequate mechanics ensure acceptable AROM of the glenohumeral and scapulothoracic joints. If isotonic strengthening is initiated before proper mechanics are established then such activity may reinforce poor mechanics and potentially lead to undue soft tissue stress. When starting isotonic strengthening we recommend a low weight high repetition format. The utilization of a lawn chair approach, starting the patient in supine, gradually increasing the incline of the surface they are lying on to ultimately performing the exercises in standing may be a useful technique of progression. Periscapular isotonic strengthening should begin at this time, however, dislocation precautions must continue to be taken into consideration when instructing patients in specific exercises. IR and ER isotonic strengthening should be performed in the plane of the scapula. Due to a significantly impaired or absent rotator cuff, clinicians

and patients need to appreciate that active IR or ER ROM activity will be difficult or impossible to isolate subscapularis or infraspinatus/teres minor either during strengthening or with ADLs.

Phase III, involving moderate strengthening at twelve weeks, is initiated when the patient demonstrates appropriate P/AA/AROM of the operative shoulder. The patient should also be able to isotonicly activate each portion of the deltoid and periscapular musculature while demonstrating appropriate shoulder mechanics. The patient should be tolerating gentle resistive strengthening of the elbow, wrist and hand of the operative upper extremity.

The primary goals of phase III are to demonstrate and maintain pain free appropriate shoulder mechanics, advance strengthening program, and increase patient's functional independence. Dislocation precautions must continue to be followed for all static and dynamic activities. We recommend all strengthening exercises to be based on the principles of low weight high repetitions to enhance shoulder endurance and minimize the risk of injury / dislocation. We have found that most patients following rTSA have achieved functional strength gains by following progressive resisted exercises up to 1.36 kg (3 lbs) based on DeLorme's<sup>7</sup> principles of progressive resistive exercise. Sudden lifting, pushing, and jerking motions are avoided indefinitely to again minimize the risk of injury / dislocation.

Phase IV occurs when the patient has been discharged from skilled PT to continue with an independent progressive HEP. To enter phase IV the patient must be able to maintain pain free shoulder AROM while demonstrating appropriate posture and shoulder mechanics. The patient is expected to be independent with an appropriate strengthening progression program. Ultimate postoperative shoulder ROM is typically 80-120deg of elevation with functional ER to 30deg. Functional use of the operative shoulder is demonstrated by a return to light household, work and leisure activities as recommended by the patient's surgeon and physical therapist.

### **Frequency & Duration:**

Inpatient Stay: Daily or as indicated by patients status and progression.

Outpatient Care: 2x/week for 2-3 months as indicated by patient's status and progression. The start of outpatient therapy may be delayed 3-6weeks if the rTSA was completed for a revision arthroplasty and/or in the presence of poor tissue (soft tissue and/or bone) integrity. The treating therapist must consult with the referring surgeon regarding this. Reading and understanding the operative note is strongly recommended.

**Patient / family education:**

1. Instruction in pain control and ways to minimize inflammation
2. Don/doffing of specific shoulder immobilizer and cryocuff
3. Appropriate positioning in supine and seated positions
4. Instruction in activity level modification / joint protection / precautions
5. Instruction in appropriate HEP (home exercise program)

**Re-evaluation / assessment**

- Standard Time Frame: 30 days or less as clinically appropriate/necessary.

**Discharge Planning:**

Transfer of Care: N/A unless patient is referred back to surgeon prior to arrange follow-up or to a physical therapist in the community if the patient wishes to complete their rehabilitation closer to home. Patient is to be sent with a copy of the BWH rTSA protocol and standard of care.

Patient's discharge instructions: Continue with individualized home program indefinitely to ensure maintenance of ROM, strength, and function.

**Authors:**

Stephanie Boudreau, PT  
Reg B. Wilcox III, PT  
9/2007

**Reviewers:**

Debbie Canoa, PT  
Lina Penikas, PT  
Janice McInnes, PT

## References

1. Arntz CT, Jackins S, Matsen FA,3rd. Prosthetic replacement of the shoulder for the treatment of defects in the rotator cuff and the surface of the glenohumeral joint. *J Bone Joint Surg Am.* 1993;75(4):485-491.
2. Arntz CT, Matsen FA,3rd, Jackins S. Surgical management of complex irreparable rotator cuff deficiency. *J Arthroplasty.* 1991;6(4):363-370.
3. Bayley I, Kessel L, eds. *Shoulder Surgery.* Berlin, Heidelberg, New York: Springer-Verlag; 1982.
4. Beaton D, Richards RR. Assessing the reliability and responsiveness of 5 shoulder questionnaires. *J Shoulder Elbow Surg.* 1998; 7: 565-572.
5. Boileau P, Watkinson DJ, Hatzidakis AM, Balg F. Grammont reverse prosthesis: design, rationale, and biomechanics. *J Shoulder Elbow Surg.* 2005;14(1 Suppl S):147S-161S.
6. Boulahia A, Edwards TB, Walch G, Baratta RV. Early results of a reverse design prosthesis in the treatment of arthritis of the shoulder in elderly patients with a large rotator cuff tear. *Orthopedics.* 2002;25(2):129-133.
7. DeLorme T, Wilkins AL. *Progressive Resistance Exercise.* New York: Appleton-Century-Crofts; 1951.
8. Field LD, Dines DM, Zabinski SJ, Warren RF. Hemiarthroplasty of the shoulder for rotator cuff arthropathy. *J Shoulder Elbow Surg.* 1997;6(1):18-23.
9. Frankle M, Siegal S, Pupello D, Saleem A, Mighell M, Vasey M. The Reverse Shoulder Prosthesis for glenohumeral arthritis associated with severe rotator cuff deficiency. A minimum two-year follow-up study of sixty patients. *J Bone Joint Surg Am.* 2005;87(8):1697-1705.
10. Fukuda K, Chen CM, Cofield RH, Chao EY. Biomechanical analysis of stability and fixation strength of total shoulder prostheses. *Orthopedics.* 1988;11(1):141-149.
11. Grammont PM, Baulot E. Delta shoulder prosthesis for rotator cuff rupture. *Orthopedics.* 1993;16(1):65-68.
12. Laurence M. Replacement arthroplasty of the rotator cuff deficient shoulder. *J Bone Joint Surg Br.* 1991;73(6):916-919.
13. Levy O, Copeland SA. Cementless surface replacement arthroplasty of the shoulder. 5- to 10-year results with the Copeland mark-2 prosthesis. *J Bone Joint Surg Br.* 2001;83(2):213-221.

14. Lippitt SB, Harryman DT II, Matsen FA III. A practical tool for evaluating function. The simple shoulder test. In: Matsen FA, Fu FH, Hawkins RJ, editors. *The shoulder: a balance of mobility and stability*. American Academy of Orthopedic Surgeons. 1993: 501-518.
15. Matsen FA, Antoniou J, Rozencaiwig R, Campbell B, Smith KL. Correlates with comfort and function after total shoulder arthroplasty for degenerative joint disease. *J Shoulder Elbow Surg* 2000; 9(6): 465-469.
16. Matsen FA III, Ziegler DW, DeBartolo SE. Patient self-assessment of health status and function in glenohumeral degenerative joint Disease. *J Shoulder Elbow Surg*. 1995; 4: 345-351.
17. Neer CS, 2nd, Watson KC, Stanton FJ. Recent experience in total shoulder replacement. *J Bone Joint Surg Am*. 1982;64(3):319-337.
18. Noyes FR, DeMaio M, Mangine RE. Evaluation-based protocols: a new approach to rehabilitation. *Orthopedics*. 1991;14(12):1383-1385.
19. Nwakama AC, Cofield RH, Kavanagh BF, Loehr JF. Semiconstrained total shoulder arthroplasty for glenohumeral arthritis and massive rotator cuff tearing. *J Shoulder Elbow Surg*. 2000;9(4):302-307.
20. O'Brien SJ, Warren RF, Schwartz E. Anterior shoulder instability. *Orthop Clin North Am*. 1987;18(3):395-408.
21. Richards R, An KN, Bigliani LU, Friedman R J, Gartsman G M, Gristina AG, Iannotti JP, Mow VC, Sidles JA, Zuckerman JD. A standardized method for the assessment of shoulder function. *J Shoulder and Elbow Surg*. 1994; 3: 347-352.
22. Sanchez-Sotelo J, Cofield RH, Rowland CM. Shoulder hemiarthroplasty for glenohumeral arthritis associated with severe rotator cuff deficiency. *J Bone Joint Surg Am*. 2001;83-A(12):1814-1822.
23. Sarris IK, Papadimitriou NG, Sotereanos DG. Bipolar hemiarthroplasty for chronic rotator cuff tear arthropathy. *J Arthroplasty*. 2003;18(2):169-173.
24. Speer KP, Warren RF, Horowitz L. The efficacy of cryotherapy in the postoperative shoulder. *J Shoulder Elbow Surg*. 1996;5(1):62-68.
25. Werner CM, Steinmann PA, Gilbert M, Gerber C. Treatment of painful pseudoparesis due to irreparable rotator cuff dysfunction with the Delta III reverse-ball-and-socket total shoulder prosthesis. *J Bone Joint Surg Am*. 2005;87(7):1476-1486.
26. Williams GR, Jr, Rockwood CA, Jr. Hemiarthroplasty in rotator cuff-deficient shoulders. *J Shoulder Elbow Surg*. 1996;5(5):362-367.

27. Zuckerman JD, Scott AJ, Gallagher MA. Hemiarthroplasty for cuff tear arthropathy. *J Shoulder Elbow Surg.* 2000;9(3):169-172.