

around the central matrix. The outer diameters of the circular profile of filaments seen surrounding the electron-lucent matrix in transverse sections were the same as in the longitudinal section, with the single exception of the smaller incomplete forms (Fig. 2, A). The outer diameters in this case were approximately 740 Å. It is interesting to note that the cylinder structures were always enveloped by the cell processes.

Discussion. The organization of the vertebrate retina has become increasingly well recognized in recent years.^{4,9} The present paper describes in detail for the first time the ultrastructural characteristics of cylinder-like structures (termed the cylinder organelle) present in the horizontal cell processes. Previous reports of this structure in the human retina have included only a partial description of its ultrastructural detail.^{1,2}

Certain other specialized structures in this area have been described but appear morphologically distinct from the cylinder organelle: Evans⁴ found parallel fibers of electron-dense material in chick rod endings. In 1967, Matsusaka⁵ described a structure in the synaptic cytoplasm of chick retina cone. He found stacks of paired membranes and called them lamellar bodies. In serial sections, Mountford⁶ described a structure in the receptor-bipolar synaptic area of the guinea pig retina and described it as spindle-shaped with cross striations. Pedler and Tilly⁷ observed a banded structure in Rhesus macaque monkeys; they reported that it extended for approximately 37 sections, having a length of approximately 3 μ. In a study by Leuenberger⁸ paracrystalline inclusions were observed within the inner segments and the synaptic pedicles of the human photoreceptor cells. These inclusions are formed by microfilaments, 150 Å in diameter and showing regular spacing.

We would speculate that the cylinder structure apparently has gone unnoticed in previous studies, perhaps in part because of different orientations of the specimen block. The structure may also be more observable under certain pathologic conditions, and there may be some significance in the fact that all of the present specimens having the cylinder structure were from eyes with melanomas. In the present cases, however, the melanomas were distant from the areas where the cylinder organelles were seen. We do not believe the cylinder organelles to be artifacts, as we have not seen it in many other animal or human retinas, other ocular tissues or tumors similarly processed.

At the present time the origin and function of the cylinder-like structure is unknown. Its close physical relationship with the synaptic vesicles might suggest that it is involved in the synaptic functions of the retina rod cells or horizontal cell processes.

From the Section of Tumor Research and Pathology, Department of Ophthalmology and Visual Science, Yale University School of Medicine, New Haven, Conn. Supported in part by National Institutes of Health Grant EY 00108-06. Submitted for publication Aug. 12, 1975. Reprint requests: J. Craft, Department of Ophthalmology and Visual Science, Yale University School of Medicine, 333 Cedar St., New Haven, Conn. 06510.

REFERENCES

1. Hogan, M. J., Alvarado, J. A., and Weddell, J. E.: *Histology of the Human Eye*, Philadelphia, 1971, W. B. Saunders Company.
2. Radnot, M., and Lovas, B.: Die Ultrastruktur der Photoreceptor-Synapsen in einem Falle von Sehnervenatrophie, *Albrecht v. Graefes Arch. Klin. Exp. Ophthalmol.* **173**: 56, 1967.
3. Hebel, R.: Über ein Körperchen mit regelmässiger Innenstruktur in einer Synapse der äusseren plexiformen Schicht des Hundeauges, *Albrecht v. Graefes Arch. Klin. Exp. Ophthalmol.* **180**: 38, 1970.
4. Evans, E. M.: On the ultrastructure of the synaptic region of visual receptors in certain vertebrates, *Z. Zellforsch. Mikrosk. Anat.* **71**: 499, 1966.
5. Matsusaka, T.: Lamellar bodies in the synaptic cytoplasm of the accessory cone from the chick retina as revealed by electron microscopy, *J. Ultrastr. Res.* **18**: 55, 1967.
6. Mountford, S.: Filamentous organelles in receptor-bipolar synapses of the retina, *J. Ultrastr. Res.* **10**: 207, 1964.
7. Pedler, C. M. H., and Tilly, R.: *Eye Structure*, Eleventh Symposium, Stuttgart, 1965, Schattauer Verlag.
8. Leuenberger, P. M.: Mikrofilamentartige Einschlüsse in den Photoreceptorsynapsen der menschlichen Netzhaut, *J. Microscopie* **15**: 79, 1972.
9. Dowling, J. E.: Organization of vertebrate retinas, *INVEST. OPHTHALMOL.* **9**: 655, 1970.

Crossing axons in the third nerve nucleus.

DON C. BIENFANG.

The research presented in this paper studied the pathway taken by the crossed fibers of the third nerve nucleus in an animal whose nucleus has been well mapped and found to correlate well with higher mammals and man. Autoradiography using tritiated amino acid labeled the cell bodies and axons of the left side of the oculomotor nucleus of the cat. Axons so labeled could be seen emerging from the ventral portion of the left nucleus through the median longitudinal fasciculus (mlf) to join the left oculomotor nerve. Labeled axons were also seen to emerge from the medial border of the caudal left nucleus, cross the midline, and pass through the right nucleus and the right mlf to join the right oculomotor nerve. These latter axons must be the crossed axons of the superior

rectus and levator palpebrae subnuclei. Since the path of these crossed axons is through the caudal portion of the nucleus of the opposite side, the destruction of one lateral half of the oculomotor nucleus would result in a bilateral palsy of the crossed subnuclei. Bilateral palsy of the superior rectus and bilateral asymmetrical palsy of the levator palpebrae muscles would result.

Previous investigations in the cat and the monkey have established that the branch of the third nerve to the superior rectus consists entirely of crossed fibers, and that the branch to the levator palpebrae consists of both crossed and uncrossed fibers.¹⁻³ This suggests that all the axons from the superior rectus and some from the levator palpebrae must cross the mesencephalic midline. The location of this crossing and the subsequent path taken by these crossed fibers has not been well studied though some suggestive information is available.^{4, 5}

Stains for central nervous system myelin or for neuron fibers easily demonstrate an abundance of nerve fibers crossing the midline between the paired third nerve nuclei of the cat. Though present throughout the rostro-caudal extent of the nucleus, they are most prominent in the caudal one-third, suggesting that they are axons of the superior rectus, inferior oblique, and levator palpebrae subnuclei located there.^{2, 3}

However, Cajal⁶ pointed out on the basis of Golgi studies of the third nerve nucleus that there are two other potential sources for crossing fibers in this nucleus, namely axons of afferents to the nucleus, e.g., from the vestibular nuclei,⁷ and dendrites of the cell bodies of the third nerve nucleus.

Positive identification of these crossed fibers as the axons of the cell bodies of the opposite side could be made with a whole neuron marking technique such as autoradiography.

Radioactive amino acids, when injected in the vicinity of neurons, are taken up by the soma, incorporated into the protein of the cell, and ultimately distributed along the course of the entire cell thus labeling the cell body and the course of its axon.⁸ This new tracing device offers great promise for neuro-anatomic mapping since the amino acid is not taken up by axons passing through the region of the injection but only by cell bodies at the site of the injection. The cells that incorporate the radioactive amino acid identify themselves by labeling their cell bodies.

Technique. Five adult cats weighing from two to four kilograms were used. The cats were premedicated with 50 mg. of pentobarbital given intraperitoneally. Atropine sulphate, 0.1 mg. was given subcutaneously and the animals were deeply anesthetized with intramuscular ketamine hydrochloride. The head was placed in a stereotactic

head holder and an occipital craniotomy was performed. A small amount of the tip of the bony tentorium was removed to allow the stereotactic placement of a glass micropipette into the left third cranial nerve nucleus. The micropipettes had previously been loaded with 1 to 2 μ Ci of desiccated tritiated proline or leucine. The dry amino acid was redissolved in a small amount of normal saline at the time of the experiment. The bolus of approximately 0.5 to 1.0 μ liters of solution was injected into the region of the left third nerve nucleus through the hydraulic pressure created by a Hamilton syringe connected to the micropipette with polyethylene tubing.

The scalp wound was sutured and the animals were killed after one week. The brains were fixed in 10 per cent formaldehyde buffered to pH 7.4, and the brain stem was processed for paraffin sectioning. Sections were cut at 10 micra and one section of every twenty was mounted. The mounted sections were processed down to the water stage and then dipped in $\frac{3}{4}$ strength Kodak NTB-2 photographic emulsion. They were stored in dry, light-free boxes in a freezer at -13° C. for six weeks and developed in Dektol. The sections were lightly stained with toluidine blue.

Results. In three of the five cats the caudal portion of the third nerve nucleus was labeled. These three cats demonstrated radiolabeled axons that originated in the left third nerve nucleus, crossed the midline, and entered the right third nerve after passing through the right third nerve nucleus. Since proline seemed to have a greater tendency to label small cells than leucine, and hence showed less contrast, the results were more striking with leucine. This differential uptake has been noted in other areas of the brain.⁹ With both amino acids, an abundance of radioactive fibers can be shown exiting from the ventral portion of the left nucleus destined for the muscles innervated by uncrossed axons. On the opposite side, exiting from the ventral portion of the right nucleus are radioactive fibers that have had their origin in cell bodies on the left side of the midline (Figs. 1 and 2).

The details of these crossing fibers is shown in Fig. 3. It should be noted that these radioactive axons cross the midline in the dorsoventral center of the nucleus and plunge into the mass of cell bodies of the opposite side before exiting through the medial longitudinal fasciculus to form the intramedullary portion of the third nerve. The level at which these crossing fibers are seen passing through the right third nerve nucleus would correspond to the location of the superior rectus, inferior oblique, and part of the levator palpebrae subnuclei.

Indirect evidence to support these findings was supplied by the two experiments which failed to inject the caudal third nerve nucleus. In one, only

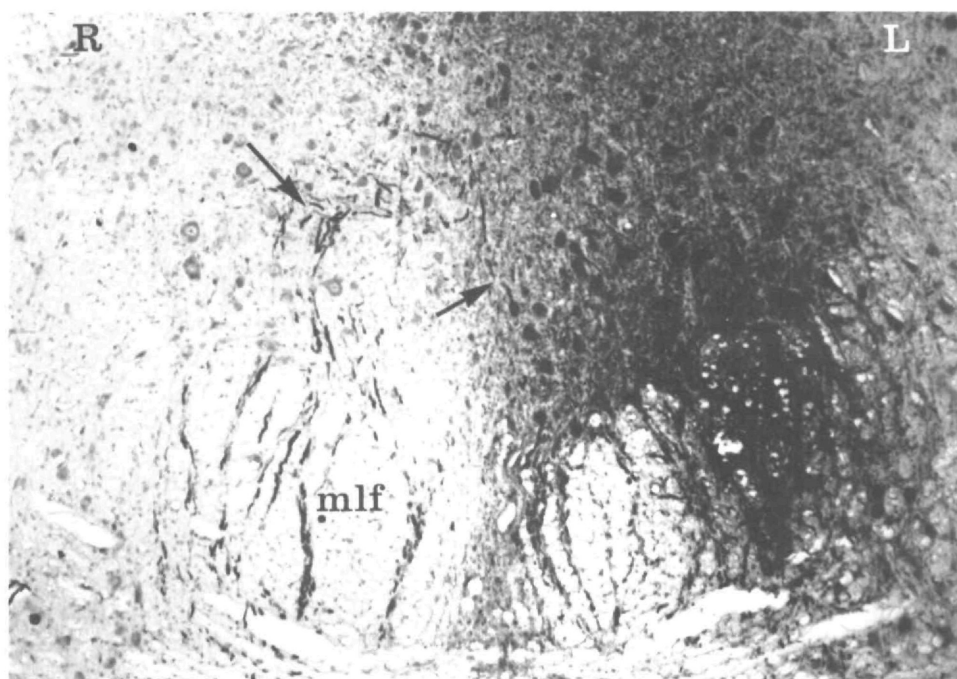


Fig. 1. Autoradiograph and toluidine blue, $\times 50$, the caudal third nerve nucleus in cross-section. The blackness overlying the large neuronal soma on the left side of the nucleus indicates they have incorporated the radioactive leucine. None of the neuronal soma in the right side of the nucleus are labeled. Axons which have incorporated radioactivity are seen streaming out of the left nucleus (arrow), passing through the right nucleus (arrow) and the right mlf to join the third nerve. Uncrossed axons are seen exiting through the left mlf.

the rostral half of the third nerve nucleus was injected. No crossing fibers were seen and no radioactive fibers were seen in the contralateral third nerve. In the second, the periaqueductal grey matter and the left fourth nerve nucleus were injected but not the third nerve nucleus. Once again, no crossed fibers were seen in the third nerve nucleus or in the third nerve. Since these latter two experiments bracket the area of interest they indicate that the crossed fibers observed did not come from cells in the vicinity of the caudal half of the third nerve nucleus.

Finally, no cells of the interstitial nucleus, the superior colliculus or the vestibular nuclei were labeled in any of the experiments.

Discussion. Positive identification of the source of the abundant axons crossing in the caudal third nerve nucleus rests on a whole neuron marking technique. Since the autoradiographic injection can only label an axon by first reaching its cell body, the labeled axons exiting from the right ventral third nerve nucleus after crossing the midline must have originated from cells in the left third nucleus. No others cells with known projections to the third nerve nucleus were ever labeled.

The organization of the third nerve nucleus of the cat has been the most thoroughly studied.

There are many articles in the French and German literature of the late nineteenth and early twentieth century postulating the existence of crossed axons in the third cranial nerve and its nucleus. With the exception of the articles by Perlia,⁴ Van Gehuchten,⁵ and Cajal,⁶ they fail to positively identify the course and location of these crossed fibers. Thus, although the proof of the origin of these crossed fibers from the superior rectus and levator palpebrae subnuclei could have been deduced from the fiber degeneration studies of Perlia⁴ and Van Gehuchten⁵ or from the Golgi stains of Cajal,⁶ these were done in the rabbit and mouse, respectively, and do not have as much pertinence to the human as does the cat.

The fact that the axons of the superior rectus subnucleus of one side cross the midline and pass through the superior rectus subnucleus of the other side implies that if one side of the third nerve nucleus is destroyed there will result a bilateral paralysis of superior rectus function. Since the axons of the levator palpebrae subnucleus are mixed-crossed and uncrossed, the lids would be expected to exhibit profound ipsilateral ptosis and partial contralateral ptosis.

Since the anatomy of the third nerve nucleus in man resembles that of the cat with respect to

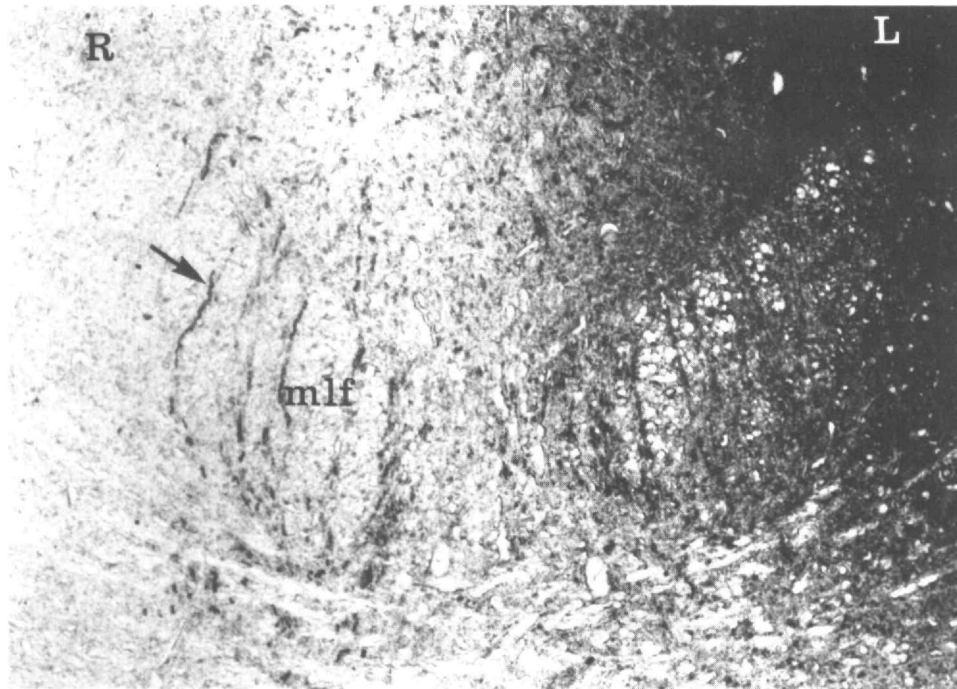


Fig. 2. Same as Fig. 1 except that radioactive proline was used. Many small cells (probably glia) as well as the large cells are labeled in the left side of the third nerve nucleus. No large cells of the right nucleus are labeled. Labeled crossed axons are seen exiting from the right ventral portion of the nucleus (arrow) through the mlf.

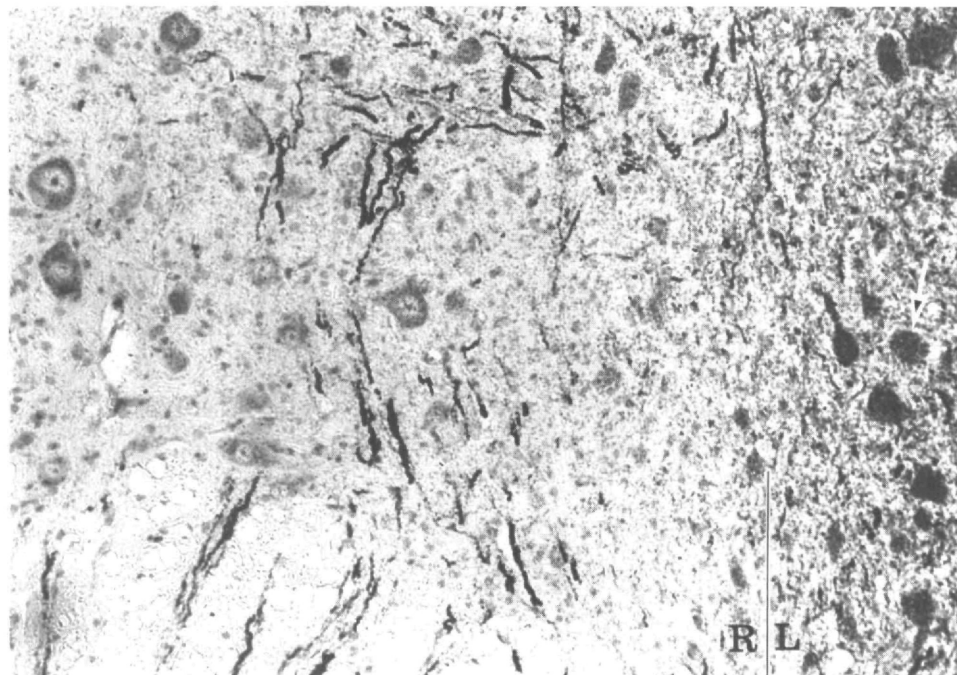


Fig. 3. Detail of Fig. 1 $\times 120$. The radioactive change over the neuronal soma in the right side of the nucleus is no greater than the background in contrast to the neurons of the left side (arrow). Midline indicated by vertical lines.

the location of as yet unidentified crossed axons,¹⁰ the clinical neurologic findings following destruction of one lateral half of the third cranial nerve nucleus may be similar.

From the Howe Laboratory of Ophthalmology, Massachusetts Eye and Ear Infirmary, 243 Charles St., Boston, Mass. 02114. This work was supported by NEI National Education Institute Grant No. EY 01 370-01. Submitted for publication July 2, 1975. Reprint requests: Dr. Bienfang.

Key words: oculomotor nucleus, superior rectus, levator palpebrae, autoradiography, axons.

REFERENCES

1. Warwick, R.: Oculomotor Organization, pp. 173-204. In "The Oculomotor System" Bender, M. B., editor, New York, 1964, Harper and Row, pp. 173-204.
2. Gacek, R. R.: Localization of neurons supplying the extraocular muscles in the kitten using horseradish peroxidase, *Exp. Neurol.* **44**: 381, 1974.
3. Bienfang, D. C.: Location of the cell bodies of the superior rectus and inferior oblique motoneurons in the cat, *Exp. Neurol.* **21**: 455, 1968.
4. Perlia: Die Anatomie des Oculomotorius-centrums beim Menschen, *Arch Ophthalmol.* **35**:4: 287, 1889.
5. Van Gehuchten, A.: Recherches sur l'origine et le trajet intracerebral des Nerfs moteurs par la Methode de la degenerescence Wallerienne indirecte, *Le Nevraxe*, **5**: 265, 1903.
6. Ramon y Cajal, S.: *Histologie du systeme nerveux*, Paris, 1909-1911, vol. 2, p. 237.
7. Gacek, R. R.: Anatomical Demonstration of the Vestibulo-Ocular Projections in the Cat, *Laryngoscope* **81**: 1595, 1971.
8. Cowan, W. M., Gottlieb, D. I., Hendrickson, A. E., et al.: The autoradiographic demonstration of axonal connections in the central nervous system, *Br. Res.* **37**, **21**: 51, 1972.
9. Kuenzle, H., and Cuenod, M.: Differential uptake of (³H) proline and (³H) leucine by neurons: its importance for the autoradiographic tracing of pathways. *Br. Res.* **62**: 213, 1973.
10. Pearson, A. A.: The oculomotor nucleus in the human fetus, *J. Comp. Neurol.* **80**: 47, 1944.

Electrophysiologic evidence for normal optic nerve fiber projections in normally pigmented squinters. GLEN L. MCCORMACK.

The Siamese cat, a type of albino, has a visual pathway anomaly in which too many optic nerve fibers cross at the optic chiasm, and also frequently has strabismus. The correlation of strabis-

mus with this defect suggests that a similar pathway defect without pigmentation anomalies, may be the cause of much human strabismus. Creel, Witkop, and King⁸ have used evoked potential methods to show that such a pathway defect likely occurs in the human albino. While unpublished control experiments verified their results on human albinos, no such defect has been found in the normally-pigmented human squinter. It is concluded that the visual pathway anomaly is limited to albinism and is not a likely cause of most human strabismus.

The causes of human squint (strabismus) are usually unknown, especially in terms of specific neurologic models. In a rather small percentage of cases, pathologic or mechanical factors can be shown to be the primary cause. In most cases, however, no demonstrable pathologic or mechanical involvement can be found which would be significant enough to cause strabismus. These cases usually fall under the broad classification known as "concomitant"^{*} squint; a classification which would include a possible cause of strabismus which is to be tested here. Since anatomic or physiologic research is reasonably quite limited in human squinters, it is necessary to look toward animal studies for possible models of human strabismus. It is true, however, that naturally occurring squint in binocular animals other than man is virtually nonexistent, so any binocular animal showing such a squint deserves consideration as a model for human squint. The Siamese cat is one such animal.

In 1974, Guillery¹ described the unusual visual pathway defect of Siamese cats in which ganglion cell axons arising from the central temporal hemiretinas of each eye cross at the optic chiasm instead of taking the normal ipsilateral course. Since all visual centers in the Siamese cat's brain receive mismatched retinotopic inputs from the eyes, the binocular vision necessary to maintain ocular alignment would presumably not be available, and squint would be predicted. Squint does in fact occur very commonly in Siamese cats, and would seem to be of the concomitant type described above. Mechanical adhesions in the periorbital adnexa do occur in some Siamese cats,² but they are the exception and are not frequent enough to explain the incidence of squint in Siamese cats.

The Siamese cat would then seem to be a potentially good model for concomitant human squint, but a difficulty in the viability of this model for the human arises from the fact that

^{*}Concomitant strabismus can be defined as that class of strabismus where the angle of deviation between the eyes does not change in the various directions of gaze. While "accommodative" strabismus is technically included in this definition, this report is not directed toward accommodative strabismus.