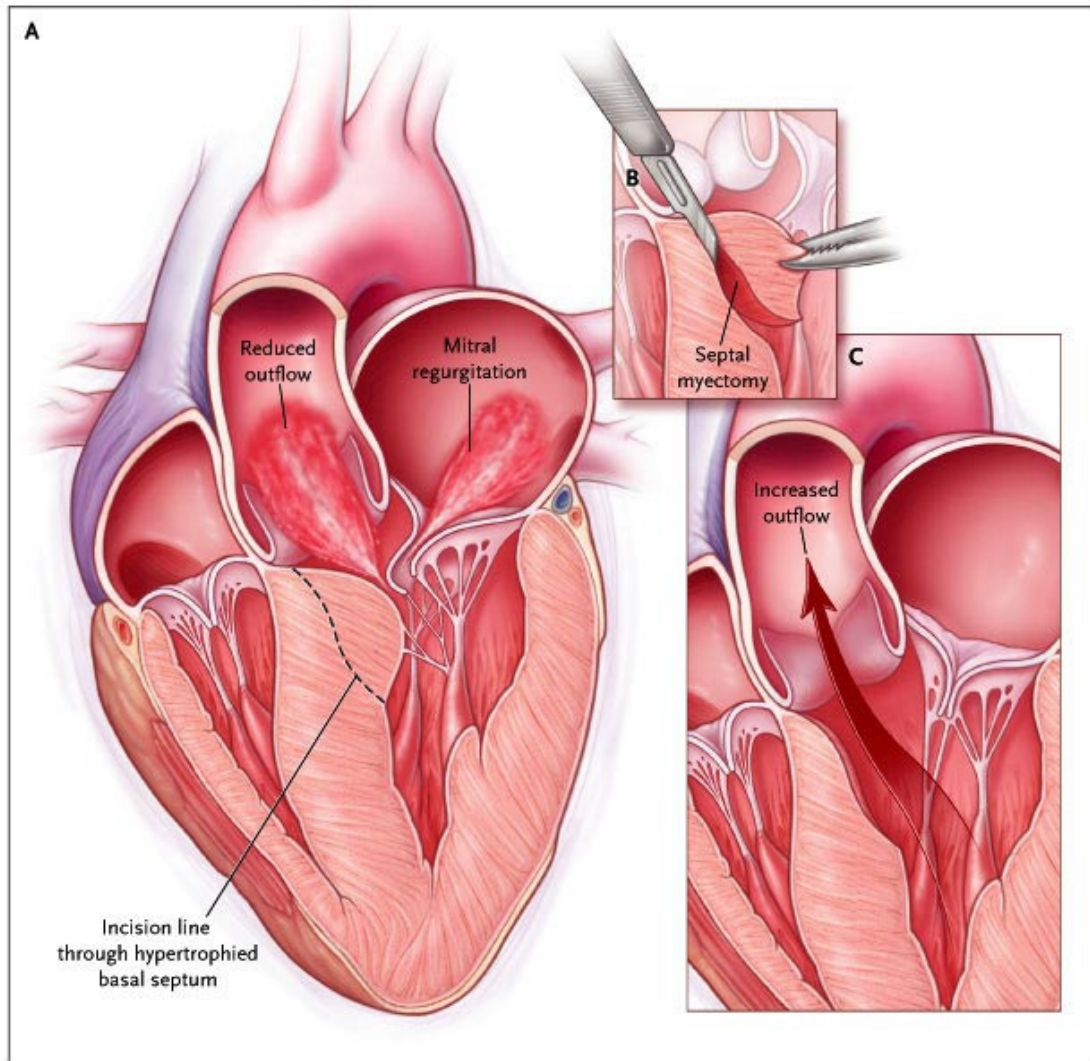


Schematic Diagram of a Patient Undergoing Surgical Septal Myectomy



Nishimura, R. A. et al. N Engl J Med 2004;350:1320-1327. Copyright © 2004 Massachusetts Medical Society. All rights reserved.